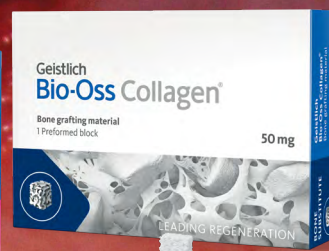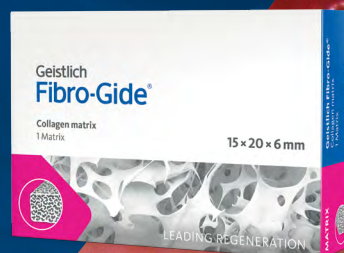

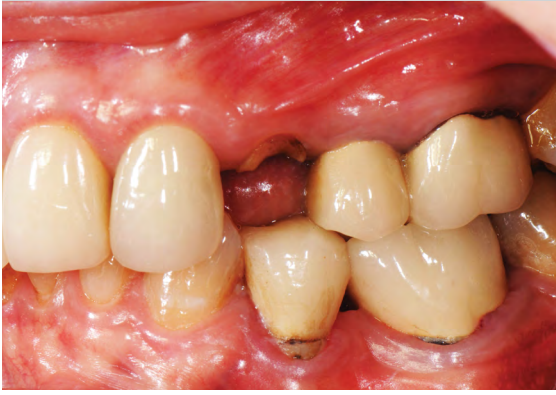
A CASE REPORT BY
ROBERT A. LEVINE,
D.D.S., FCPP, FISPPS

Phenotype Conversion Using Geistlich Fibro-Gide® for Immediate Implants in the Esthetic Zone





▶ The Situation

A healthy non-smoking 50-year old female patient who desires a single tooth solution to replace a non-restorable tooth, #12. A root fracture at the level of the palatal post was diagnosed in a root canaled tooth. Maintaining esthetics of the adjacent teeth is important as they are also restored with single full coverage porcelain crowns. Lastly, treatment time reduction and a minimally invasive surgical technique are desired by the patient for reduced downtime and post-operative morbidity.

▶ The Risk Profile

Esthetic Risk Factors	Low Risk	Medium Risk	High Risk
Patient's health	Intact immune system	Light smoker	Impaired immune system
Patient's esthetic requirements	Low	Medium	High
Height of smile line	Low	Medium	High
Gingival biotype	Thick - "low scalloped"	Medium - "medium scalloped"	Thin - "high scalloped"
Shape of dental crowns	Rectangular		Triangular
Infection at implant sight	None	Chronic	Acute
Bone height at adjacent tooth site	≤ 5 mm from contact point	5.5 - 6.5 mm from contact point	≥ 7 mm from contact point
Restorative status of adjacent tooth	Intact		Restored
Width of tooth gap	1 tooth (≥ 7 mm)	1 tooth (≤ 7 mm)	2 teeth or more
Soft tissue anatomy	Intact		Compromised
Bone anatomy of the alveolar ridge	No defect	Horizontal defect	Vertical defect

Patients Esthetic Expectations: Realistic
 Facial Bone Wall Phenotype: High Risk (<1mm)
 Esthetic Risk Profile (ERP) = Medium (summary of above)

* Note: Risk Profile Chart adapted from ITI Treatment Guide¹



SPECIAL INTERESTS
 Esthetic Zone
 Implant Placement &
 Guided Bone
 Regeneration

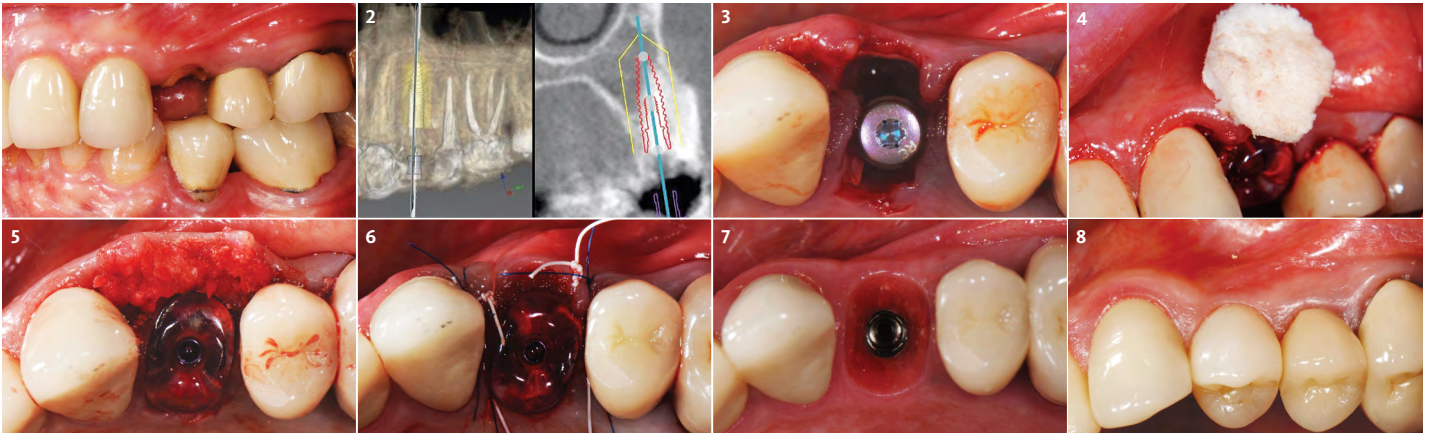
"High esthetic demands were the primary concern with this case. They were addressed with the diagnostic tools of clinical photos, a site specific CBCT to evaluate the buccal wall status, and summing the findings with patient expectations gathered using the Esthetic Risk Assessment (knee-to-knee; eye-to-eye) which is used along with our consent agreement to treatment."*

ROBERT A. LEVINE, DDS, FICPP, FISPPS, PHILADELPHIA, PA
 Periodontist

Robert A. Levine DDS is a board-certified periodontist at the Pennsylvania Center for Dental Implants and Periodontics in Philadelphia. He is a Fellow of the International Team for Dental Implantology (ITI), College of Physicians in Philadelphia, International Society of Periodontal Plastic Surgeons and the Academy of Osseointegration. He has post-graduate periodontology and implantology teaching appointments at Temple University in Philadelphia, UNC in Chapel Hill and UIC in Chicago and has over 80 scientific publications.

► The Approach

A minimally invasive surgical removal of tooth #12 with maintenance of the buccal plate and leaving a 3mm buccal gap. The implant will be placed one mm below the level of the intact buccal plate with an anatomically correct surgical guide template to provide for a screw-retained solution. The gap will be filled with Geistlich Bio-Oss Collagen® to maintain the bone buccal to the implant, and a palate free approach utilizing Geistlich Fibro-Gide® for soft tissue thickening to accomplish “phenotype conversion.” The long-term surgical goal is >2-3mm thickness of both hard and soft tissue buccal to the implant.



- 1 Pre-operative assessment demonstrates minimal zone and thickness of buccal keratinized gingiva, with a medium periodontal phenotype.
- 2 Pre-operative CBCT with virtually planned implant placement. A thin buccal plate (<1mm) is measured. Good apical bone is noted for the placement of a Straumann® 12mmx4.1mm bone level tapered implant.
- 3 Minimally invasive removal of #12 using only a buccal approach mini-flap showing an intact buccal plate with immediate placement of the implant (1 mm below the intact buccal wall) in a screw-retained position. A 3mm buccal gap is measured and a 1.5mm palatal gap.
- 4 Both the buccal and palatal gaps have been packed with Geistlich Bio-Oss Collagen® hydrated with Gem 21S. It's my preference to squeeze Geistlich Fibro-Gide® between thumb and forefinger, prior to placement. A dry-carved piece of Geistlich Fibro-Gide® is in position thinned approximately 2mm with beveling laterally and coronally with a new #15 blade.
- 5 Geistlich Fibro-Gide® in place facial to the intact buccal wall under a full thickness buccal approach mini-flap. Immediate contour management was completed using an Anatotemp® for a maxillary bicuspid tooth.
- 6 Suturing completed using 4-0 PTFE and 5-0 polypropylene non-resorbable sutures. Anticipated short-term 25% post-operative swelling is discussed with the patient.
- 7 3 months post-operative appointment showing a well-developed subgingival transition zone created with immediate contour management. A reverse torque test was completed, and the case proceeded to completion.
- 8 9 month post-operative view with final screw-retained crown in place. Good interproximal papilla healing is noted with thickening of the buccal periodontal phenotype compared with Fig. #1. (Restorative Therapy: Drew Shulman DMD, MAGD; Philadelphia, PA)

SOFT TISSUE VOLUME

Geistlich Fibro-Gide® works well for gingival augmentation

“Virtual planning the implant width for a screw-retained prosthesis based on an intact buccal wall after extraction to allow for a buccal gap of >2mm to be grafted are important keys for esthetic success.”

(See image to the left)

► The Outcome

Minimally invasive surgery for buccal wall maintenance, virtually planning the buccal gap and implant width, using a xenograft in the buccal gap with phenotype conversion using a volume stable collagen matrix in conjunction with immediate contour management, allows for the best chance for papillae fill interproximally and maintenance of the mid-buccal gingival margin long-term.

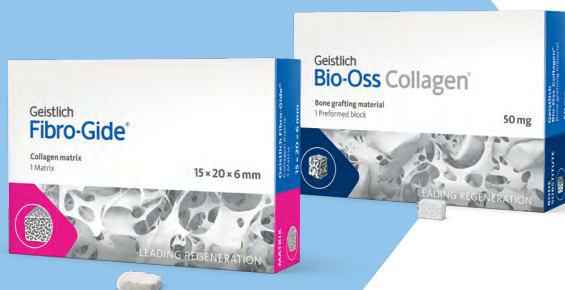Briefly Speaking

► Keys to Success

1. Using the ERP for all esthetic zone patients and sharing with all members of the “team”.
2. Using the “10 Keys”^{2,3} concept sequentially as our diagnostic, surgical and prosthetic “check-list” to avoid an esthetic complication.
3. Virtual planning the implant placement to provide a buccal gap of >2mm which determines the implant width to be used in the surgical procedure.
4. Esthetic zone cases are a complex treatment requiring a team approach (SAC: Classification Straightforward, Advanced, Complex). The surgeon, restorative dentist and dental laboratory all need to be on the same page for the benefit of the patient.
5. Treating a “Realistic Patient” who is a part of the conversation from the start and understands the steps in the procedure and any limitations they may have based on their ERP, is important.

► My Biomaterials

Geistlich Fibro-Gide® is a volume-stable collagen matrix specifically designed for soft tissue regeneration. As an alternative to connective tissue grafts, it is ideally suited for augmentation around natural teeth and implants.



► My Instruments

1. Good clinical documentation of the case from the start using a good quality camera (Nikon D-90 for intra & extra-oral evaluation and case documentation)
2. PIEZOSURGERY® (Tips: Ex1, Ex2, OT7S 3, OT4, IM2A, IM2P)
3. Hu-Friedy PMPIX Buser Membrane Instrument
4. Salvin Nordland Bendable Blade & Handle
5. Urban Mini Me Microsurgical Periosteal Elevator for buccal flap reflection (PF 1WDS1MK)
6. Salvin Curved Titanium Pocket Packer 1.75mm Radius
7. Straumann® bone level tapered implant
8. Anatotemp® (pre-molar/canine) for immediate contour mangement
9. Cytoplast® PTFE 4-0 sutures, 5-0 Glycolon (violet color) 3/8th premium reverse cutting needle

“The PIEZOSURGERY® device by Mectron is helpful in the maintenance of the critical buccal plate for minimally invasive extractions.

It is important to use ONLY when the tissue is flapped and under copious amounts of cool irrigation to prevent overheating of the osseous tissue.”



Geistlich Fibro-Gide® and Geistlich Bio-Oss Collagen® provide soft tissue volume and long-term stability

“The importance of the “one-two punch” of ROUTINE phenotype-conversion using Geistlich Fibro-Gide® in conjunction with bone grafting the >2mm buccal gap with Geistlich BioOss-Collagen® provides excellent buccal convex tissue maintenance long-term.”

- 1 ITI Treatment Guide #10 W. Martin, V. Chappuis, D. Morton, D. Buser; 29-46; Quintessence (2017).
- 2 10 Keys for Successful Esthetic-Zone Single Immediate Implants, Robert A. Levine, DDS; Jeffrey Ganeles, DMD; Luiz Gonzaga, DDS, MS; Joseph Y. Kan, DDS, MS; Harry Randel, DMD; Chris D. Evans, BDS, MSc, MRACDS; and Stephen T. Chen, BDS, MSc, PhD, FRACDS. (2017) Compend Contin Educ Dent. 38(4): 248-260
- 3 10 Keys for Successful Esthetic-Zone Single Immediate Implants: Importance of Biotype Conversion for Lasting Success Robert A. Levine, DDS; Jeffrey Ganeles, DMD; Joseph Kan, DDS, MS; and Phil L. Fava, DMD. (2018) Compend Contin Educ Dent. 39(8): 522-530

▶ [Click here to view the webinar](#)

Geistlich Pharma North America, Inc.

Princeton, NJ 08540

Customer Care Toll-free: 855-799-5500

info@geistlich-na.com

dental.geistlich-na.com

ABOUT BIOBRIEF

We know that exposure to new or refined treatment approaches brings innovation to practice. Geistlich Biomaterials is pleased to introduce a periodic opportunity to get up close and personal with creative clinicians from around the world. Focused on peer-to-peer exchange, BIOBRIEF features clinically relevant cases and techniques in specific therapeutic areas – highlighted with valuable insights about materials and instrumentation, as well as KEYS TO SUCCESS.

Geistlich Biomaterials – bringing you *regeneration on time*.

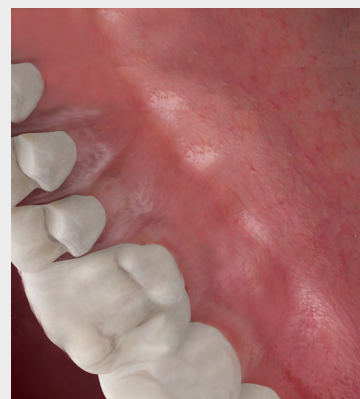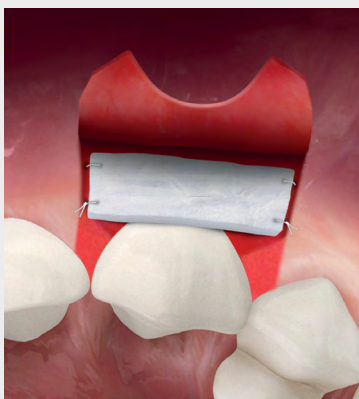▶ Palate Free Innovation

At Geistlich, over 165+ years of collagen expertise has fueled soft tissue advancement with a selection of matrices to expand therapeutic options in both open and closed healing situations.

The result is an evolution in care – a palate free approach. Positively impacting patient satisfaction with faster treatment times and considerably less pain and discomfort.



For more information visit: palatefree.com



CAUTION: Federal law restricts these devices to sale by or on the order of a dentist or physician.

Indications:

Geistlich Fibro-Gide® is indicated for the following uses: Soft tissue augmentation; localized gingival augmentation to increase keratinized tissue around teeth and implants; Alveolar ridge reconstruction for prosthetic treatment; and recession defects for root coverage.

Warnings:

As Geistlich Fibro-Gide® is a collagen product, allergic reactions may not be totally excluded. Possible complications which may occur with any surgery include swelling at the surgical site, flap sloughing, bleeding, dehiscence, hematoma, increased sensitivity and pain, redness and local inflammation.

Indications:

Geistlich Bio-Oss Collagen® is indicated for the following uses: Augmentation or reconstructive treatment of the alveolar ridge; Filling of periodontal defects; Filling of defects after root resection, apicoectomy, and cystectomy; Filling of extraction sockets to enhance preservation of the alveolar ridge; Elevation of the maxillary sinus floor; Filling of periodontal defects in conjunction with products intended for Guided Tissue Regeneration (GTR) and Guided Bone Regeneration (GBR); and Filling of peri-implant defects in conjunction with products intended for GBR.

Warnings:

Possible complications which may occur with any surgery include swelling at the surgical site, flap sloughing, bleeding, local inflammation, bone loss, infection or pain. As Geistlich Bio-Oss Collagen® contains collagen, in very rare circumstances cases of allergic reactions may occur.

For more information on contraindications, precautions, and directions for use, please refer to the Geistlich Bio-Oss Collagen® and Geistlich BioGide® Instructions for Use at: dental.geistlich-na.com/ifu